

Manuscript version

## Malignant catarrhal fever: A review

George C. Russell <sup>a,\*</sup>, James P. Stewart <sup>b</sup>, David M. Haig <sup>a</sup>

<sup>a</sup> *Moredun Research Institute, Edinburgh, Scotland, UK*

<sup>b</sup> *Division of Medical Microbiology, University of Liverpool, Liverpool, England, UK*

Accepted 7 November 2007

---

Malignant catarrhal fever (MCF) is a fatal lymphoproliferative disease of cattle and other ungulates caused by the ruminant  $\gamma$ -herpesviruses alcelaphine herpesvirus 1 (AIHV-1) and ovine herpesvirus 2 (OvHV-2). These viruses cause inapparent infection in their reservoir hosts (wildebeest for AIHV-1 and sheep for OvHV-2), but fatal lymphoproliferative disease when they infect MCF-susceptible hosts, including cattle, deer, bison, water buffalo and pigs. MCF is an important disease wherever reservoir and MCF-susceptible species mix and currently is a particular problem in Bali cattle in Indonesia, bison in the USA and in pastoralist cattle herds in Eastern and Southern Africa.

MCF is characterised by the accumulation of lymphocytes (predominantly CD8<sup>+</sup> T lymphocytes) in a variety of organs, often associated with tissue necrosis. Only a small proportion of these lymphocytes appear to contain virus, although recent results with virus gene-specific probes indicate that more infected cells may be present than previously thought. The tissue damage in MCF is hypothesised to be caused by the indiscriminate activity of MHC-unrestricted cytotoxic T/natural killer cells. The pathogenesis of MCF and the virus life cycle are poorly understood and, currently, there is no effective disease control.

Recent sequencing of the OvHV-2 genome and construction of an AIHV-1 bacterial artificial chromosome (BAC) are facilitating studies to understand the pathogenesis of this extraordinary disease. Furthermore, new and improved methods of disease diagnosis have been developed and promising vaccine strategies are being tested. The next few years are likely to be exciting and productive for MCF research.

*Keywords:* Malignant catarrhal fever; Ovine herpesvirus 2; Alcelaphine herpesvirus 1; Cattle; Deer; Pathogenesis; Diagnosis

---

\* Corresponding author. Tel.: +44 131 445 5111; fax: +131 445 6111.

*E-mail address:* [george.russell@moredun.ac.uk](mailto:george.russell@moredun.ac.uk) (G.C. Russell).

## Introduction

Malignant catarrhal fever (MCF) is a dramatic, fatal disease of cattle and other ungulates, including deer, bison (*Bison bison*) and pigs, caused by the ruminant  $\gamma$ -herpesviruses alcelaphine herpesvirus 1 (AIHV-1) and ovine herpesvirus 2 (OvHV-2) (Reid and Buxton, 1984a; Loken et al., 1998; Schultheiss et al., 2000). The disease is characterised by fever, inappetence and ocular and nasal discharge. Death can occur within a few days or up to several weeks after the onset of clinical signs.

Two forms of MCF were originally described, with distinct geographical distributions. In Africa, MCF was first recorded as disease outbreaks in cattle caused by transmission of the infectious agent from wildebeest (*Connochaetes taurinus*), which are inapparent carriers (Plowright et al., 1960). Wildebeest-associated MCF (WA-MCF) is a particular problem with pastoralists in Eastern and Southern Africa, where wildebeest are found (Cleaveland et al., 2001; Bedelian et al., 2007). WA-MCF also has been a problem in zoological collections that contain wildebeest (Meteyer et al., 1989; Whittaker et al., 2007).

The other common form of the disease is sheep-associated MCF (SA-MCF), which was initially observed in Europe, but is found worldwide wherever sheep and cattle (or other MCF-susceptible species) are kept together. SA-MCF currently is an important economic and welfare problem in Bali cattle (banteng; *Bos javanicus*) in Indonesia and in bison in the USA. The disease has been reported worldwide, including in North and South America (Reid and Robinson 1987; Berezowski et al., 2005; Rech et al., 2005), Europe (Collery and Foley, 1996; Frolich et al., 1998; Desmecht et al., 1999; Yus et al., 1999), the Middle East (Brenner et al., 2002; Abu Elzein et al., 2003), Asia (Dabak and Bulut, 2003), Africa (Rossiter, 1981) and New Zealand (Wilson, 2002;). As MCF surveillance has extended worldwide, so too has the recorded MCF-susceptible host range. As well as being diagnosed in pigs (Albini et al., 2003; Syrjälä et al., 2006), MCF has been reported in captive moose (*Alces alces*; Clauss et al., 2002) and water buffalo (*Bubalus bubalis*; Martucciello et al., 2006).

The best characterised causative agents of MCF are the two  $\gamma$ -herpesviruses alcelaphine herpesvirus 1 (AIHV-1) and ovine herpesvirus 2 (OvHV-2). AIHV-1 is present in wildebeest and is a known cause of WA-MCF. OvHV-2 is present in sheep and is a known cause of SA-MCF. An interesting feature of MCF is that the natural reservoir species for the viruses causing MCF (wildebeest and sheep) do not exhibit any clinical signs of infection, whereas the disease is dramatic and usually fatal in MCF-susceptible species, some of which are closely phylogenetically related to the reservoir hosts. There are excellent animal models of MCF. Rabbits and hamsters can be infected with AIHV-1 or OvHV-2 and develop a MCF-like syndrome that is very similar to that seen in species naturally susceptible to MCF (Anderson et al., 2007; Buxton and Reid, 1980; Buxton et al., 1984, 1988; Jacoby et al., 1988; Reid et al., 1989a).

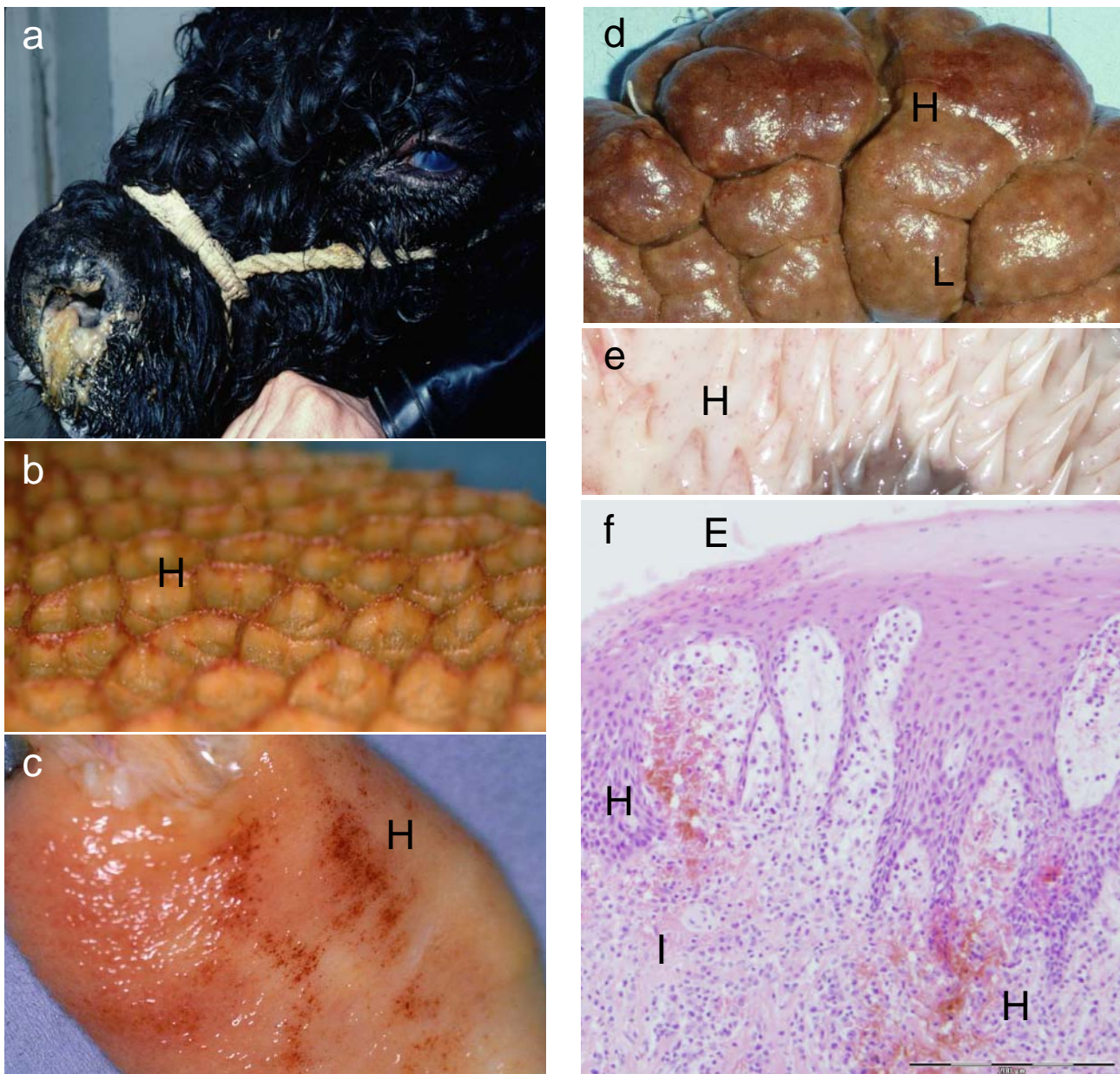
A feature of MCF, with respect to cattle, is that many outbreaks are sporadic, with single or only a few individuals in a herd being affected. However, occasionally there are more serious outbreaks that can affect up to 40% of a herd. The reasons for this are not known. Certain species of deer, e.g., Père David's (*Elaphurus davidianus*; Reid et al., 1987), Bali cattle (Wiyono et al., 1994) and bison (Berezowski et al., 2005) appear to be particularly susceptible to MCF in terms of rapid death following clinical signs and the proportion of animals affected in closed herds. In cattle, recovery from MCF has been recorded (Milne and Reid, 1990; O'Toole et al., 1997; Penny, 1998). The purpose of this review is to describe recent advances in our understanding of MCF, with particular attention to molecular virology, pathogenesis and diagnosis.

## Clinical signs and pathology of MCF

Several overlapping but distinct patterns of clinical disease have been described for MCF in cattle: peracute, head and eye, alimentary, neurological and cutaneous (OIE, 2004). The head and eye form is the most common expression of disease in cattle. Typical signs include fever, inappetence, ocular and nasal discharge (Fig. 1a), lesions of the buccal cavity and muzzle, diarrhoea and depression. The clinical signs depend to some extent on the species infected, the virus and how long the animal survives after the onset of clinical signs. Many deer die within 48 h of the first clinical signs and affected bison generally die within 3 days (O'Toole et al. 2002). In contrast, cattle may survive for a week or more.

Gross findings at postmortem examination include petechial haemorrhages on the tongue, buccal mucosa, in the gastrointestinal and respiratory tracts and urinary bladder (Fig. 1b-d). Commonly, there are raised pale foci on the surfaces of the kidneys (Fig. 1e) and these may extend into the cortex. There is

general enlargement of lymph nodes. Histologically, MCF is characterised by the accumulation of lymphocytes in a range of tissues, some of these being associated with vasculitis and necrotic lesions (Fig. 1f).

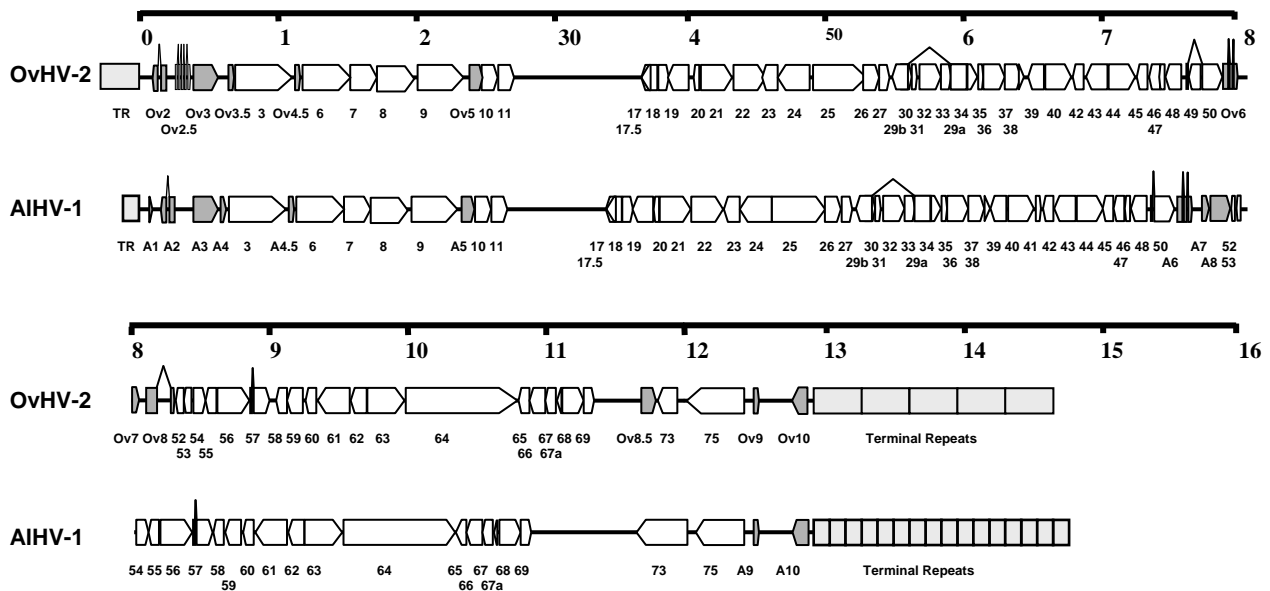


**Fig. 1.** Gross and histological signs of MCF. (a) Dexter bull showing classic head-and-eye signs of MCF with corneal opacity and mucopurulent nasal discharge; (b-e), MCF lesions on reticulum, urinary bladder, kidney and buccal papillae, respectively; H indicates areas of haemorrhage and L indicates pale focal lesions on the kidney; (f), haematoxylin and eosin-stained section of buccal papillae with early MCF lesions; in addition to areas of haemorrhage (H), the section shows epidermal erosion (E) and areas of early lymphocyte infiltration (I).

## Genome structure and classification of MCF-associated viruses

The two viruses known to cause MCF are well characterised and the genomes have been sequenced (Ensser et al., 1997; Coulter et al 2001; Hart et al., 2007) (Fig. 2). AIHV-1 and OvHV-2 belong to the Genus *Rhadinovirus* of the Subfamily *Gammaherpesvirinae* (McGeoch et al., 2005). The recent sequencing of OvHV-2 from a large granular lymphocyte (LGL) cell line derived from a cow has revealed that its genome is highly similar to AIHV-1 and is co-linear with the other known rhadinoviruses (Hart et al., 2007) (Fig. 2). The genomes have unique segments of about 130 kbp, bounded by terminal repeats of 1.1 kbp (AIHV-1; Ensser et al., 1997) or 4.2 kbp (OvHV-2; Hart et al., 2007).

There are 73 predicted open reading frames (ORFs) in the OvHV-2 sequence, compared with 71 in AIHV-1 (Hart et al., 2007). Of the 10 unique genes described in AIHV-1 (A1-A10; Ensser et al., 1997), eight have clear homologues in OvHV-2: there are no equivalents of A1 or A4 (Fig. 2; Table 1). OvHV-2 encodes additional unique genes, designated Ov2.5, Ov3.5, Ov4.5 and Ov8.5 to indicate their positions relative to neighbouring unique genes (Table 1). Thus, Ov2.5 lies between Ov2 and Ov3 (homologues of A2 and A3) and encodes a spliced IL-10 homologue. This gene reproduces the host IL-10 splice sites exactly, but has greatly reduced intron sizes. The expressed recombinant Ov2.5 protein has typical cellular IL-10 functions (Jayawardane et al., 2008).



**Fig. 2.** Genome organisation of AIHV-1 and OvHV-2. Schematic maps show the relative organisation of genes in the OvHV-2 and AIHV-1 genomes. Genes are shown to scale as block arrows indicating the position and orientation of open reading frames. Gene designations are given beneath, following the numbering scheme for *Herpesvirus saimiri*. Conserved  $\gamma$ -herpesvirus genes are shown as open arrows, while genes found only in the MCF virus genomes are shaded grey and named beneath each map with an A prefix for AIHV-1-specific genes and Ov prefix for OvHV-2. The terminal repeat (TR) sequences are shown to scale and are shaded pale grey.

Ov3.5 occupies a position analogous to A4, but has no obvious sequence similarity. Both genes encode small proteins with predicted signal sequences and so may perform similar functions. Ov4.5 lies between ORFs 3-6 of OvHV-2 and AIHV-1 carries an homologous gene (A4.5), which was not annotated originally (Ensser et al., 1997, Mills et al., 2003; Fig. 2). The Ov4.5 and A4.5 predicted protein sequences have similarity to the Epstein-Barr virus BALF1 gene product and the Bcl-2 family of apoptosis-related proteins and therefore may be involved in the regulation of cell death. Ov8.5 lies between ORF69 and ORF73 in OvHV-2 and encodes a proline-rich protein of unknown function. Expression of these unique

genes of OvHV-2 has been demonstrated recently in LGL lines derived from MCF-affected rabbits and cattle, suggesting that they are genuine (Thonur et al., 2006).

**Table 1**  
**Unique MCF virus genes**

OvHV-2 gene	AIHV-1 gene	Possible Function <sup>a</sup>
	A1	Unknown
Ov2	A2	Leucine zipper protein; Transcription regulation
Ov2.5		Viral IL-10
Ov3	A3	Semaphorin homologue; Intracellular signalling
Ov3.5		Unknown, signal peptide
	A4	Unknown, signal peptide
Ov4.5	A4.5	Bcl-2 homologue; cell death regulators
Ov5	A5	GPCR (G-protein coupled receptor); Intracellular signalling
Ov6	A6	Similar to Epstein-Barr virus BZLF1; Viral transactivator
Ov7	A7	Virus Glycoprotein
Ov8	A8	Virus Glycoprotein
Ov8.5		Unknown, proline-rich
Ov9	A9	Bcl-2 homologue; Cell death regulators
Ov10	A10	Nuclear localisation signal; Transcriptional regulation?

<sup>a</sup> Provisional assignment of function is based on analysis of the predicted amino acid sequences and similarity to proteins of known function.

Less frequently, MCF associated with other  $\gamma$ -herpesviruses has been described in deer and experimental animals. Hippotragine herpesvirus-1, recovered in culture from cells of a roan antelope (*Hippotragus equinus*), was able to induce MCF on inoculation into rabbits (Reid and Bridgen, 1991). Another  $\gamma$ -herpesvirus has been detected in white-tailed deer (*Odocoileus virginianus*) showing clinical signs of MCF and with anti-MCF antibodies, but no detectable AIHV-1 or OvHV-2 DNA (Li et al. 2000). The MCF virus of white-tailed deer has been characterised by limited sequencing, but its natural reservoir has not been identified. Caprine herpesvirus-2 appears to be endemic in at least some goat populations (Li et al 2001a) and has been associated with MCF-like lesions, characterised by lymphocytic infiltration, in a range of cervid species (Crawford et al 2002; Vikoren et al., 2007).

In parallel with the sequencing of OvHV-2 derived in the UK from a clinically affected cow (Hart et al., 2007), a second OvHV-2 sequence recently has been determined from OvHV-2 virus particles isolated in the USA from the nasal secretions of 13 sheep (Taus et al., 2007). The two sequences are highly similar, with amino acid identities of 94-100% between corresponding ORFs, except for ORF73. Much of the ORF73 gene is taken up by three tandem repeat elements and the sequence could not be determined clearly from pooled viral DNA. ORF73 cloned from three individual sheep were 94-98% identical, differing mainly by insertions/deletions in one of the repeat regions.

The UK isolate, in contrast, differed by multiple insertions/deletions within repeat areas and by over 20 missense changes, concentrated in the N-terminal part of the protein sequence (Hart et al., 2007). The C-terminal 130 residue segment of ORF73 was highly conserved in all isolates, with only one missense difference recorded in the UK isolate. This gene therefore appears to be highly variable, both within and between geographical isolates of OvHV-2, and may be a useful tool for epidemiological studies of OvHV-2 variation. The ORF73 protein is known to be antigenic (see below) and it is possible that its variation reflects rapid evolution (relative to other genes) in the presence of immunological pressure from the host.

The expansion of herpesvirus sequence availability and the use of polymerase chain reaction (PCR) as a diagnostic tool have facilitated phylogenetic analysis both within the rhadinoviruses and across all herpesvirus groups (Li et al., 2005b; McGeoch et al., 2005, 2006). These analyses have led to the suggestion that the  $\gamma$ -herpesviruses should be split into four genera rather than two, with the current *Rhadinovirus* Genus being divided to form two additional Genera, *Macavirus* (including AIHV-1 and presumably OvHV-2) and

*Percavirus*, based on likelihood of co-evolutionary origin (McGeoch et al., 2006). AIHV-1 and OvHV-2 are most closely related to porcine lymphotropic herpesvirus-1 (McGeoch et al., 2005, 2006).

An analysis of over 20 ruminant rhadinoviruses based on the amino acid sequence of a fragment of the DNA polymerase gene suggested they could be divided into two major subgroups, one of which contained MCF viruses that express the 15A epitope, used previously to identify MCF virus infection, and a second group of lymphotropic herpesviruses that do not express the 15A epitope (Li et al., 2005b). Both of these clades are likely to lie within the *Macavirus* Genus described above. Bovine herpesvirus 4 was not grouped with either of these clades by sequence analysis, in agreement with other analyses that suggested that BoHV-4 had diverged further from other artiodactyl  $\gamma$ -herpesviruses and was retained in the *Rhadinovirus* Genus (McGeoch et al., 2005; 2006).

The study of MCF pathogenesis has been facilitated by the recent production of a bacterial artificial chromosome (BAC) clone carrying the entire pathogenic AIHV-1 genome (Dewals et al., 2006). This clone propagated infectious AIHV-1 virus in permissive cells and produced MCF in rabbits that was indistinguishable from the disease caused by non-recombinant virus. The AIHV-1 BAC is currently proving a useful tool for analysing the contribution of individual genes to the pathogenesis and host range of MCF and will move our understanding of MCF pathogenesis to a new level.

### **Cell biology of MCF viruses**

A feature of AIHV-1 is that it is predominantly cell-associated on primary isolation in culture and probably also in tissues of MCF-susceptible species. OvHV-2 has never been propagated in monolayer culture, although an incompletely enveloped virus has been detected by electron microscopy (EM) from an infected rabbit LGL lysate (Rosbottom et al., 2002). The absence of a permissive cell culture system has limited the study of OvHV-2 and the search for such a system continues to be a priority.

In contrast, AIHV-1 replicates as cell-free, as well as cell-associated, virus that is virulent (in terms of inducing disease in rabbits or cattle) for up to five passages in culture in bovine turbinate cells seeded with free virus. Cell-free and cell-associated virus also is produced by cultured lymphoid cells from MCF-affected rabbits. After five passages, there is a period during which the viral genome undergoes rearrangements, leading to attenuation. These rearrangements involve gene deletions and translocations from the central region of the genome to the terminal repeat region (Wright et al., 2003). Later, after >20 passages in culture, AIHV-1 becomes cell-free and is attenuated with respect to disease induction in animals. Thus, cell-free virulent and attenuated AIHV-1 virus can be produced for vaccine and pathogenesis studies.

The receptors used by the virus to enter cells (epithelial or lymphocyte) to establish latent or lytic infection are not known and this currently is the focus of a collaborative study by the authors. The cellular site of virus production in wildebeest or sheep that allows cell-free virus to be shed in nasal and ocular secretions is not known. Although OvHV-2 transcripts and DNA can be detected in ovine blood leucocytes, the particular cellular site of latency is not known.

### **Transmission of MCF-associated viruses**

Both AIHV-1 and OvHV-2 appear to be transmitted by contact or aerosol, mainly from wildebeest calves (AIHV-1) and lambs (OvHV-2) under 1-year old (Mushi et al., 1981; Baxter et al., 1997; Li et al., 1998). Incubation periods after experimental inoculation of cattle are 2-12 weeks (Plowright et al., 1975; Buxton et al., 1984; Taus et al., 2006). The causal viruses are passed between individuals of the reservoir hosts and from reservoir to MCF-susceptible species by the horizontal route, although vertical transmission has been inferred from the detection of anti-MCF virus antibodies in the serum of some gnotobiotic or specific-pathogen-free lambs (Rossiter, 1981) and from recovery of AIHV-1 from a wildebeest fetus (Plowright, 1965). The principal source of free virus in wildebeest is in the tears and nasal secretions (Mushi et al., 1981). OvHV-2 viral DNA also has been detected in samples from the alimentary, respiratory and urogenital tracts of sheep (Hussy et al., 2002). This may account for some infection of offspring occurring during or shortly after lambing or calving.

Experimental induction of MCF in cattle has been achieved using wildebeest nasal secretions containing AIHV-1 (Plowright, 1964). Infectious OvHV-2 is present in ovine nasal secretions, but appears to

be difficult to isolate from this source, since the period of virus shedding is short for any given animal (Kim et al., 2003; Li et al., 2004). OvHV-2 collected from ovine nasal secretions will infect naïve sheep (Taus et al., 2005) and also can induce MCF in cattle and bison (Taus et al., 2006).

While sheep and bison can be infected by intranasal nebulisation with  $10^3$ - $10^5$  genome copies of OvHV-2, infection of cattle is not reliable, even at 1,000-fold higher doses (Taus et al., 2005; 2006). At very high doses, intranasal inoculation of OvHV-2 induced MCF-like clinical signs in naïve sheep, confirming a previous report that this carrier species can develop a mild form of MCF (Buxton et al. 1985, Li et al., 2005a).

The MCF-susceptible species generally are thought to be dead-end hosts that do not transmit virus to other animals, which has the beneficial effect of limiting the spread of disease during outbreaks. Some transmission between infected deer has been reported, although such cases appear to be unusual (Reid et al., 1986). The reason for lack of spread between MCF-susceptible animals is likely to be that the virus replicates in a cell-associated manner in these species and cell-free virus is not produced.

### **MCF-associated viruses in tissues**

A characteristic of MCF is that, despite the profound pathological changes seen, there is little evidence of viral antigen in affected organs, although viral DNA can be detected by in situ hybridisation or PCR (Bridgen et al., 1992; Baxter et al., 1997). In rabbits, the disease is seen as a progressive T cell hyperplasia involving local proliferation and infiltration of both lymphoid and non-lymphoid organs, associated with extensive vasculitis. This is followed by tissue destruction caused by dysregulated cytotoxic lymphocytes (Buxton et al., 1984; Schock and Reid, 1996).

More recently, a detailed analysis of MCF in rabbits (Anderson et al., 2007) has confirmed and extended earlier observations, showing specific differences between MCF caused by OvHV-2 and AIHV-1 (Table 2). OvHV-2-associated lesions were more apparent in visceral lymphoid tissue (e.g., mesenteric lymph nodes), whereas lesions associated with AIHV-1 were more frequent in peripheral lymph nodes. In addition, OvHV-2 associated lesions contained more areas of necrosis than those of AIHV-1.

However, with both viruses, lymphoid cell infiltrations consisted mainly of T cells, of which  $CD8^+$  T cells predominated, with very few  $CD4^+$  T cells. However, a proportion of the infiltrating T cells were neither  $CD4^+$  nor  $CD8^+$  (Anderson et al., 2007). Interestingly, in addition to  $CD8^+$  T cells,  $CD8^-CD4^-$  LGL lines (see below) infected with OvHV-2 have been isolated from rabbits, cattle and deer (Burrells and Reid, 1991; Swa et al., 2001).

A small proportion of virus-infected cells have been detected in AIHV-1-infected animals by indirect immunofluorescence (Patel and Edington, 1981) and in situ hybridisation (Bridgen et al., 1992), suggesting that T cell hyperplasia may not always be due to the proliferation of infected cells. Treating infected rabbits with cyclosporin A suppressed lymphocyte proliferation, but did not prevent establishment of necrotic lesions and lethal MCF, showing that hyperplasia was not critical to the development of MCF (Buxton et al., 1984).

The small numbers of infected lymphocytes observed in lesions characterised by lymphocyte accumulation have been interpreted to suggest that MCF has an autoimmune-like pathology, caused by the cytotoxic action of uninfected cells under the regulatory influence of a small number of infected cells (Buxton et al., 1984; Reid et al., 1984b; Schock and Reid, 1996). However, more recent work is challenging this view. In situ PCR has shown that vascular lesions in the brains of MCF-affected cattle and bison contained  $CD8^+$  OvHV-2-infected lymphocytes in larger numbers than has been previously recorded (Simon et al., 2003). Furthermore, preliminary data from the Moredun group (D.M. Haig et al., unpublished data) indicates that several viral gene sequences or gene products can be detected by in situ hybridisation in many more lymphocytes accumulating at various tissue sites in OvHV-2-infected rabbits than has previously been seen.

This raises the possibility that the pathogenesis of MCF is due to the direct action of virus-infected, dysregulated cytotoxic T cells at sites of lesions and that the frequency of virus positive cells in vivo has been underestimated. It also indicates that LGLs obtained in culture from MCF-affected tissues are likely to be biologically relevant effector cells that are derived from and representative of the infected cells in vivo.

Table 2

Comparison of histopathology of MCF induced by AIHV-1 and OvHV-2 in rabbits (based on Anderson et al., 2007)

Observation <sup>a</sup>	AIHV-1	OvHV-2	Comments
Haemorrhagic foci in appendix	–	+	
Necrosis in lymphoid follicles of appendix	–	+	
Pan-T positive cells in appendix	+++	++	Mainly in interfollicular areas
CD4 T cells in appendix	++	+	Mainly in interfollicular areas
CD8 T cells in appendix	++	+	Throughout lymphoid areas
B cells in appendix	++	+	Lymphoid areas
Necrosis in MLN	–	+	
CD8 T cells in MLN	++	+	Cortex and medulla
MHC class II positive cells in MLN	+	++	Margins of follicles
CD8 T cells in spleen	++	+	Mainly in periarteriolar lymphoid sheath
Liver periportal lymphoid cell accumulations	+++	++	Large and numerous, with little debris or apoptotic cells, in AIHV-1 infection; Moderate size and frequency, with cellular debris and apoptotic cells in OvHV-2 infection
Lymphoid cells in liver	++	+	In parenchyma
MHC-positive cells in liver	++	+	In clusters or in periportal accumulations
Pan-T positive cells in lung lymphoid cell accumulations	+++	++	
Kidney lymphoid cell accumulation	+++	–	Perivascular location
CD8 <sup>+</sup> in kidney	+++	+	Cortical accumulations and scattered through medulla
CD4 <sup>+</sup> cells in kidney	++	+	In lymphoid cell accumulations
MHC <sup>+</sup> cells in kidney	++	+	In some lymphoid cell accumulations

MLN: Mesenteric lymph nodes; MHC: Major histocompatibility complex

<sup>a</sup> Each observation, where differences were found, is recorded as absent (–), present (+), frequent (++), or very frequent (+++), for AIHV-1 and OvHV-2 MCF, respectively

### Large granular lymphocytes in MCF

LGLs can be cultured from various tissues of MCF-affected animals infected with OvHV-2 or AIHV-1 (Reid et al., 1983). These LGLs have cytotoxic activity and appear to have T cell or natural killer (NK) cell phenotypes (Cook and Splitter, 1988; Reid et al., 1989b; Burrells and Reid, 1991; Wilkinson et al., 1992).

In contrast to the apparent paucity of cells containing virus in MCF-affected tissues *in vivo*, >90% of LGL cells are infected with virus, as detected by immunocytochemistry or by *in situ* hybridisation for viral DNA or mRNA. Viral particles detectable by EM can be seen in the cytoplasm of AIHV-1 LGLs, but are rare in OvHV-2 LGLs (Cook and Splitter, 1988; Rosbottom et al., 2002). However, some OvHV-2-infected LGL lines of bovine or cervine origin can induce MCF when adoptively transferred to rabbits (Reid et al., 1989b). These LGLs are indiscriminately cytotoxic, killing various target tissue cells in an MHC-unrestricted fashion; they do not exhibit concanavalin A (ConA)-stimulated proliferation, whereas uninfected T cells proliferate when exposed to ConA. In the case of OvHV-2-infected LGLs, tumour necrosis factor- $\alpha$ , interferon- $\gamma$ , interleukin (IL)-4 and IL-10 are constitutively expressed (Schock et al., 1998).

The activated cytotoxic phenotype and ConA-unresponsiveness of infected LGL cell lines could be the consequence of constitutive activation of the T cell signalling molecules Lck and Fyn kinases, along with activation of downstream p42 and p44 mitogen activated protein kinases. In uninfected T cells, these are only transiently activated after stimulation of antigen and co-receptors on the T cell surface (Swa et al., 2001). The viral mechanism inducing this change in the LGLs is currently unknown.



In respect of lytic (productive) and latent virus life cycles, LGLs from OvHV-2-infected rabbit and cattle tissues have distinct features (Rosbottom et al., 2002). The cattle LGL line had viral genomes that were mainly circular, suggestive of latency, while the rabbit LGLs contained a large proportion of linear DNA, suggestive of productive replication. The rabbit cell line also expressed RNA corresponding to a lytic cycle gene (ORF75) and viral capsids could be detected after concentration of cell lysates (Rosbottom et al., 2002).

These results were confirmed and extended by the use of OvHV-2 sequence data to produce probes for the OvHV-2 unique genes (Thonur et al., 2006). In sheep peripheral blood mononuclear cells, OvHV-2 viral genomes were mainly circular and mRNA for only Ov3.5 of the unique genes was detected. In contrast, rabbit LGL cultures contained mainly linear viral DNA and expressed most of the unique genes, while bovine LGLs contained mainly circular viral genomes and also expressed most of the unique genes. Interestingly, no evidence of transcription of the latency-associated gene ORF73, or the productive cycle regulator ORF50 could be found in bovine LGLs. Treatment of the cells with the topoisomerase inhibitor doxorubicin induced unique and productive viral gene expression and linear genome production, while treatment with 5-azacytidine inhibited unique gene expression and induced circular genome accumulation in both LGL lines (Thonur et al., 2006).

Thus, it appears that LGL cell lines derived from MCF-affected animals may have features of both latent and productive life cycles, suggesting that the normal programme of viral gene expression is defective in these hosts (Thonur et al., 2006). The ability to manipulate viral gene expression and DNA replication in LGL cultures should be a useful tool for future research, with potential for generating a cell culture system for the propagation of OvHV-2.

## Diagnosis of MCF

Diagnosis of MCF depends on a combination of clinical signs, histopathology and detection of virus-specific antibodies in blood or DNA in blood or tissue samples. Diagnosis in MCF-susceptible species has benefited from recent developments in molecular virology. Sequencing of the genome of AIHV-1 (and genome fragments from other  $\gamma$ -herpesviruses) has allowed the development of both generic and specific reagents for amplification of diagnostic fragments of both AIHV-1 and OvHV-2 genomes by PCR (Bridgen and Reid, 1991; Katz et al., 1991; Baxter et al., 1993; Flach et al., 2002).

The similarity of the clinical signs to other enteric or vesicular diseases, the lack of unique disease-specific clinical diagnostic features and the variability in the presentation of the disease make laboratory confirmation of a clinical diagnosis of MCF important (Holliman, 2005). Histopathological analysis of postmortem samples should give a clear diagnosis. The World Organisation for Animal Health (OIE) recognises histopathology as the definitive diagnostic test, but laboratories have adopted other approaches, such as indirect immunofluorescence to detect antibodies specific for MCF virus antigens and PCR assays that detect MCF virus DNA sequences (OIE, 2004). Using a monoclonal antibody (mAb) (15A) specific for a conserved MCF virus antigen, a competitive inhibition (CI)-ELISA test has been developed and refined (Li et al., 1994, 2001b). A direct ELISA has been developed recently that offers a simple and inexpensive alternative to other serological tests (Fraser et al., 2006).

The use of PCR allows sensitive confirmation of the presence of MCF viruses in infected animals and may also be useful for phylogenetic and epidemiological studies in both natural and MCF-susceptible hosts. Serological or PCR-based testing of apparently healthy cattle and free-living bison and caribou (*Rangifer tarandus*) has demonstrated infection in the absence of clinical signs (Zarnke et al., 2002; Powers et al., 2005). This suggests that inapparent infection with OvHV-2 or recovery from MCF may be more frequent than was previously thought.

Conventional and real-time (quantitative) PCR assays have been developed for the detection of OvHV-2 and AIHV-1 viral DNA (Katz et al., 1991; Baxter et al., 1993; Hussy et al., 2001; Flach et al., 2002; Traul et al., 2005). The conventional assays employ a nested PCR approach, which makes them about 10-fold more sensitive than quantitative PCR. In combination with an appropriate host gene assay, however, real-time PCR assays have the potential to define viral loads in a range of tissues from both natural and MCF-susceptible hosts. The higher sensitivity of the nested PCR assays may make them an attractive alternative where viral load is low or in difficult samples, such as paraffin-embedded tissue. Detection of MCF virus-specific antibodies or DNA in an animal with clinical signs will support a diagnosis of MCF.

Several studies have used both serological and PCR-based diagnostic tests to analyse MCF infection of both reservoir and MCF-susceptible hosts. In sheep, nested PCR and CI-ELISA showed that 99% and 94% of animals tested were OvHV-2 positive, respectively, suggesting that PCR might be slightly more sensitive (Li et al., 1995a). A similar study of healthy or clinically suspect cattle concluded that PCR was more sensitive than CI-ELISA, possibly due to the rapid onset of MCF in some cases leading to death before seroconversion (Muller-Doblies et al., 1998).

A longitudinal study of 48 apparently healthy dairy cattle showed evidence of OvHV-2 DNA in blood or milk samples from 17 cattle, of which eight were also serologically positive (Powers et al., 2005). Three cattle were CI-ELISA positive but PCR negative. Detection of DNA was generally sporadic, with 1-3 positive tests within the 20 month study, while serological results were generally consistent over several months. MCF was not seen in any of the animals tested during the course of the study, suggesting that sub-clinical or latent infection with OvHV-2 can occur in cattle.

Serological studies have been conducted in a range of species that may either harbour MCF viruses or be susceptible to MCF. Some species, including sheep, goats, wildebeest and musk oxen (*Ovibos moschatus*), have a high frequency of seropositivity (>90%; Plowright, 1967; Rossiter, 1981; Li et al., 1995a, 1996; Zarnke et al., 2002), indicating their status as inapparent carriers of MCF viruses. In contrast, the degree of seropositivity in MCF-susceptible species, including cattle, bison, deer, caribou, elk (*Cervus elaphus*) and moose, ranges from a few percent to 50% seropositive (Li et al., 1996; Frolich et al., 1998; Zarnke et al., 2002; Powers et al., 2005). This variation in the frequency of MCF seroconversion suggests that infection of MCF-susceptible hosts with MCF viruses can have different outcomes that may depend on genetic variation in the host or infecting virus or on differences in the magnitude or route of challenge.

### **MCF antigens and vaccine development**

No effective treatment or vaccine for MCF has been described. Reservoir hosts and MCF-susceptible species can develop antibody responses to MCF viruses and, as discussed above, serological testing remains an important diagnostic and epidemiological tool. Antibodies that recognise AIHV-1 antigens have been demonstrated in sera from carrier sheep and MCF-affected cattle, showing that the agent responsible for SA-MCF was likely to be related to AIHV-1 (Rossiter, 1981; 1983). Further studies using immunoprecipitation and western blotting showed that both wildebeest and sheep sera recognised similar polypeptide profiles in either infected cell lysates or in purified AIHV-1 virus preparations (Herring et al., 1989; Adams and Hutt-Fletcher, 1990; Li et al., 1995b). These studies identified the major antigens recognised by the natural host species. Fewer antigens were detected by sera from cattle reacting with MCF, suggesting a more restricted pattern of gene expression in these hosts (Herring et al., 1989).

MCF virus-specific sera also have been used in attempts to identify important diagnostic or protective antigens. Antibody screening of cDNA expression libraries has led to the identification of candidate antigens from both AIHV-1 (Lahijani et al., 1995) and OvHV-2 (Coulter et al., 2002). Both studies identified cDNA clones encoding the C-terminal region of ORF73 as being antigenic in OvHV-2 positive sheep and in AIHV-1 infected rabbits and wildebeest. These ORFs encode the MCF virus homologues of the latency-associated nuclear antigen (LANA), a multifunctional protein involved in the maintenance of latency and the association of virus genomes with the host cell chromosomes. While LANA may be antigenic in latently-infected sheep or wildebeest, it is unclear how useful it would be in MCF-affected animals in either a diagnostic or protective role.

The development of mAbs against AIHV-1 antigens (Adams and Hutt-Fletcher, 1990; Li et al., 1995b) has facilitated a better understanding of the nature of the antigens recognised and allowed the development of a serological diagnostic test (Li et al., 1994). These studies described mAbs that could immunoprecipitate a glycoprotein complex with components approximately 115/110/105/78/45 kDa (mAb 12B5, Adams and Hutt-Fletcher, 1990; mAb 15-A, Li et al., 1995b). However, western blotting showed that mAb 12B5 recognised the 115-78 kDa components, while mAb 15-A recognised only the 45 kDa band. Pulse-chase experiments also suggested that the 78 and 45 kDa components were derived from larger bands by proteolytic cleavage (Adams and Hutt-Fletcher, 1990). The complex also was shown to be accessible to extrinsic labelling of AIHV-1 virions by <sup>125</sup>I, demonstrating that it was a mature virion glycoprotein complex (Adams and Hutt-Fletcher, 1990).

Recent proteomic analysis of AIHV-1 virions has shown that glycoprotein B is found in the mature virion as a complex of two furin-cleaved polypeptides of about 80 kDa (N-terminal fragment) and 50 kDa (C-terminal fragment) (I. Dry et al., unpublished data). This suggests that both 12B5 and 15-A mAbs recognise gB, that the 115/110/105/78/45 kDa complex contains the various post-translationally modified and cleaved forms of gB and that mAbs 12b5 and 15-A recognise distinct epitopes in the N-terminal and C-terminal parts of the molecule, respectively. The widespread conservation of the mAb 15A epitope in MCF viruses from both domestic and wild ungulates demonstrates the importance of this glycoprotein complex in these viruses (Li et al., 2005b), making it a good target for diagnostic or prophylactic use.

Early attempts to immunise cattle using live or inactivated formulations of the attenuated WC11 strain of AIHV-1 were unsuccessful, providing no clear protection against either parenteral or natural challenge, despite the development of virus neutralising antibodies in the serum (Piercy, 1954; Plowright 1968; Plowright et al., 1975). Later work in rabbits suggested that inactivated cell-free virulent AIHV-1 C500 strain could protect against a cell-free virus challenge, but not against a cell-associated virus challenge (Edington and Plowright, 1980). However, this work was not transferred to cattle.

Observations on the small numbers of immunised cattle that survived initial challenge suggested that their immunity was short-lived (Piercy, 1954). In contrast, cattle surviving natural infection remained immune, despite having lower titres of serum neutralising antibody than immunised animals (Plowright 1968; Plowright et al., 1975). These observations suggest that serum neutralising antibody is not a critical component of a protective immune response in cattle and raise the question of what the protective response might be. Work on cellular immunity to MCF virus has been hampered by the lack of a good experimental system in which animals can be immunised and challenged and by the severe T cell hyperplasia induced by MCF virus, which is a central part of disease pathology.

At the Moredun Research Institute, we have developed an intranasal virus challenge system intended to mimic the presumed natural route of challenge for MCF-susceptible species. Using cell-free preparations of virulent AIHV-1, experimental infection of 100% of cattle can be achieved with an incubation period of 20-50 days (Haig et al., 2008). Furthermore, cell-free high passage (in tissue culture) attenuated C500 AIHV-1 can be harvested readily and used as a vaccine candidate. This system has been used to test the proposition that a mucosal barrier of neutralising antibody could protect against disease following intranasal challenge with AIHV-1. Initial experiments have demonstrated that such an approach works, with immunised cattle protected against disease (Haig et al., 2008). These studies may allow the development of a protective vaccine for WA-MCF and provide an experimental system to study the immune response to MCF virus. Furthermore, the protective antigens in AIHV-1 can be identified and the equivalent antigens in OvHV-2 isolated to attempt vaccination control of SA-MCF.

## Conclusions

Malignant catarrhal fever is an important and fascinating disease with many unanswered questions concerning transmission, the sporadic occurrence of the disease and pathogenesis. One outstanding question is why closely related species, such as sheep and cattle, exhibit such different responses to infection with OvHV-2? The possible autoimmune pathology of MCF may provide clues to its pathogenesis and help in the identification of therapeutic treatments. The recent availability of the sequence of OvHV-2 and the development of a recombinant BAC carrying the AIHV-1 genome will greatly facilitate and accelerate our understanding of virus-host interactions. An OvHV-2 BAC clone is being sought actively.

The importance of MCF as a pathogen of farmed deer and bison, as well as cattle, is driving research for improved diagnostic tools and development of effective vaccines. The recent sequencing of the OvHV-2 genome, the production of recombinant AIHV-1 viruses and developments in the use of intranasal challenges, for both OvHV-2 and AIHV-1, constitute important steps forward in the development of vaccine strategies to protect against MCF.

## Acknowledgements

The authors are indebted to Dr David Buxton and Dr Hugh Reid for their critical reading of the manuscript. Unpublished work described in this paper was funded by the Scottish Executive Environment and Rural Affairs Department and by the UK Biotechnology and Biological Sciences Research Council.

## References

- Abu Elzein, E.M.E., Housawi, F.M.T., Gameel, A.A., Al Afaleq, A.I., El Bashir, A.M., 2003. Sheep-associated malignant catarrhal fever involving 3-5-week-old calves in Saudi Arabia. *Journal of Veterinary Medicine Series B Infectious Diseases and Veterinary Public Health* 50, 53-59.
- Adams, S.W., Hutt-Fletcher, L.M., 1990. Characterization of envelope proteins of alcelaphine herpesvirus 1. *Journal of Virology* 64, 3382-3390.
- Albini, S., Zimmermann, W., Neff, F., Ehlers, B., Hani, H., Li, H., Hussy, D., Casura, C., Engels, M., Ackermann, M., 2003. Diagnostic findings in pigs with porcine malignant catarrhal fever. *Schweizer Archiv für Tierheilkunde* 145, 61-68.
- Anderson, I.E., Buxton, D., Campbell, I., Russell, G., Davis, W.C., Hamilton, M.J., Haig D.M., 2007. Immunohistochemical study of experimental malignant catarrhal fever in rabbits. *Journal of Comparative Pathology* 136, 156-166.
- Baxter, S.I.F., Pow, I., Bridgen, A., Reid, H.W., 1993. PCR detection of the sheep-associated agent of malignant catarrhal fever. *Archives of Virology* 132, 145-159.
- Bedelian, C., Nkedianye, D., Herrero, M., 2007. Maasai perception of the impact and incidence of malignant catarrhal fever (MCF) in southern Kenya. *Preventive Veterinary Medicine* 78, 296-316.
- Baxter, S.I.F., Wiyono, A., Pow, I., Reid, H.W., 1997. Identification of ovine herpesvirus-2 infection in sheep. *Archives of Virology* 142, 823-831.
- Berezowski, J.A., Appleyard, G.D., Crawford, T.B., Haigh, J., Li, H., Middleton, D.M., O'Connor, B.P., West, K., Woodbury, M., 2005. An outbreak of sheep-associated malignant catarrhal fever in bison (*Bison bison*) after exposure to sheep at a public auction sale. *Journal of Veterinary Diagnostic Investigation* 17, 55-58.
- Brenner, J., Perl, S., Lahav, D., Garazi, S., Oved, Z., Shlosberg, A., David, D., 2002. An unusual outbreak of malignant catarrhal fever in a beef herd in Israel. *Journal of Veterinary Medicine Series B Infectious Diseases and Veterinary Public Health* 49, 304-307.
- Bridgen, A., Munro, R., Reid, H.W., 1992. The detection of alcelaphine herpesvirus-1 DNA by in situ hybridization of tissues from rabbits affected with malignant catarrhal fever. *Journal of Comparative Pathology* 106, 351-359.
- Bridgen, A., Reid, H.W., 1991. Derivation of a DNA clone corresponding to the viral agent of sheep-associated malignant catarrhal fever. *Research in Veterinary Science* 50, 38-44.
- Burrells, C., Reid, H.W., 1991. Phenotypic analysis of lymphoblastoid cell-lines derived from cattle and deer affected with sheep-associated malignant catarrhal fever. *Veterinary Immunology and Immunopathology* 29, 151-161.
- Buxton, D., Jacoby, R.O., Reid, H.W., Goodall, P.A., 1988. The pathology of sheep-associated malignant catarrhal fever in the hamster. *Journal of Comparative Pathology* 98, 155-166.
- Buxton, D., Reid, H.W., 1980. Transmission of malignant catarrhal fever to rabbits. *Veterinary Record* 106, 243-245.
- Buxton, D., Reid, H.W., Finlayson, J., Pow, I., 1984. Pathogenesis of sheep-associated malignant catarrhal fever in rabbits. *Research in Veterinary Science* 36, 205-211.
- Buxton, D., Reid, H. W., Finlayson, J., Pow, I., Berrie, E. 1985. Transmission of a malignant catarrhal fever-like syndrome to sheep: preliminary experiments. *Research in Veterinary Science* 38, 22-29.
- Clauss, M., Kienzle, E., Wiesner, H., 2002. Importance of the wasting syndrome complex in captive moose (*Alces alces*). *Zoo Biology* 21, 499-506.
- Cleaveland, S., Kusiluka, L., ole Kuwai, J., Bell, C., Kazwala, R. (2001). Assessing the impact of malignant catarrhal fever in Ngorongoro district, Tanzania. Nairobi: Community-based Animal Health and Participatory Epidemiology Unit (CAPE), Organization for African Unity.  
[http://www.eldis.org/fulltext/cape\\_new/MCF\\_Maasai\\_Tanzania.pdf](http://www.eldis.org/fulltext/cape_new/MCF_Maasai_Tanzania.pdf). Accessed 1 June 2007.
- Collery, P., Foley, A., 1996. An outbreak of malignant catarrhal fever in cattle in the Republic of Ireland. *Veterinary Record* 139, 16-17.
- Cook, C.G., Splitter, G.A., 1988. Lytic function of bovine lymphokine-activated killer cells from a normal and a malignant catarrhal fever virus-infected animal. *Veterinary Immunology and Immunopathology* 19, 105-118.
- Coulter, L.J., Reid H.W., 2002. Isolation and expression of three open reading frames from ovine herpesvirus-2. *Journal of General Virology* 83, 533-543.
- Coulter, L. J., H. Wright, H. W. Reid. 2001. Molecular genomic characterization of the viruses of malignant catarrhal fever. *Journal of Comparative Pathology* 124, 2-19.
- Crawford, T.B., Li, H., Rosenburg, S.R., Norhausen, R.W., Garner, M.M. 2002. Mural folliculitis and alopecia caused by infection with goat-associated malignant catarrhal fever virus in two Sika deer. *Journal of the American Veterinary Medical Association* 221, 843-837.
- Dabak, M., Bulut, H., 2003. Outbreak of malignant catarrhal fever in cattle in Turkey. *Veterinary Record* 152, 240-241.
- Desmecht, D., Cassart, D., Rollin, F., Coignoul, F., Tham, K.M., 1999. Molecular and clinicopathological diagnosis of non-wildebeest associated malignant catarrhal fever in Belgium. *Veterinary Record* 144, 388.
- Dewals, B., Boudry, C., Gillet, L., Markine-Goriaynoff, N., de Leval, L., Haig, D.M., Vanderplasschen, A., 2006. Cloning of the genome of alcelaphine herpesvirus 1 as an infectious and pathogenic bacterial artificial chromosome. *Journal of General Virology* 87, 509-517.

- Edington, N., Plowright, W., 1980. The protection of rabbits against the herpesvirus of malignant catarrhal fever by inactivated vaccines. *Research in Veterinary Science* 28, 384-386.
- Ensser, A., Pflanz, R., Fleckenstein, B., 1997. Primary structure of the alcelaphine herpesvirus 1 genome. *Journal of Virology* 71, 6517-6525.
- Flach, E.J., Reid, H., Pow, I., Klemm, A., 2002. Gamma herpesvirus carrier status of captive artiodactyls. *Research in Veterinary Science* 73, 93-99.
- Fraser, S.J., Nettleton, P.F., Dutia, B.M., Haig, D.M., Russell, G.C., 2006. Development of an enzyme-linked immunosorbent assay for the detection of antibodies against malignant catarrhal fever viruses in cattle serum. *Veterinary Microbiology* 116, 21-28.
- Frolich, K., Li, H., Muller-Doblies U., 1998. Serosurvey for antibodies to malignant catarrhal fever-associated viruses in free-living and captive cervids in Germany. *Journal of Wildlife Diseases* 34, 777-782.
- Haig, D.M., Grant, D., Deane, D., Campbell, I., Thomson, J., Jepson, C., Buxton, D., Russell, G.C. 2008. An immunisation strategy for the protection of cattle against alcelaphine herpesvirus-1-induced malignant catarrhal fever. *Vaccine* 26, 4461-4468.
- Hart, J., Ackermann, M., Jayawardane, G., Russell, G.C., Haig, D.M., Reid, H., Stewart, J.P., 2007. Complete sequence and analysis of the ovine herpesvirus 2 genome. *Journal of General Virology* 88, 28-39.
- Herring, A., Reid, H., Inglis, N., Pow, I., 1989. Immunoblotting analysis of the reaction of wildebeest, sheep and cattle sera with the structural antigens of alcelaphine herpesvirus-1 (malignant catarrhal fever virus). *Veterinary Microbiology* 19, 205-215.
- Holliman, A., 2005. Differential diagnosis of diseases causing oral lesions in cattle. *In Practice* 27, 2-13.
- Hussy, D., Stauber, N., Leutenegger, C.M., Rieder, S., Ackermann M., 2001. Quantitative fluorogenic PCR assay for measuring ovine herpesvirus 2 replication in sheep. *Clinical and Diagnostic Laboratory Immunology* 8, 123-128.
- Jacoby, R.O., Buxton, D., Reid, H.W., 1988. The pathology of wildebeest-associated malignant catarrhal fever in hamsters, rats and guinea-pigs. *Journal of Comparative Pathology* 98, 99-109.
- Jayawardane, G., Russell, G.C., Thomson, J., Deane, D., Cox, H., Gatherer, D., Ackermann, M., Haig, D.M., Stewart J.P. 2008. A Captured Viral IL-10 with Cellular Exon Structure. *Journal of General Virology* 89, 2447-2455.
- Katz, J., Seal, B., Ridpath, J., 1991. Molecular diagnosis of alcelaphine herpesvirus (malignant catarrhal fever) infections by nested amplification of viral DNA in bovine blood buffy coat specimens. *Journal of Veterinary Diagnostic Investigation* 3, 193-198.
- Kim, O., Li, H., Crawford, T.B., 2003. Demonstration of sheep-associated malignant catarrhal fever virions in sheep nasal secretions. *Virus Research* 98, 117-122.
- Lahijani, R.S., Sutton, S.M., Klieforth, R.B., Heuschele, W.P., 1995. Identification and analysis of an alcelaphine herpesvirus-1 (AHV-1) cDNA clone expressing a fusion protein recognized by AHV-1-neutralizing antisera. *Archives of Virology* 140, 547-561.
- Li, H., Dyer, N., Keller, J., Crawford, T.B., 2000. Newly recognized herpesvirus causing malignant catarrhal fever in white-tailed deer (*Odocoileus virginianus*). *Journal of Clinical Microbiology* 38, 1313-1318.
- Li, H., Gailbreath, K., Flach, E.J., Taus, N.S., Cooley, J., Keller, J., Russell, G.C., Knowles, D.P., Haig, D.M., Oaks, J.L., Traul, D.L., Crawford, T.B., 2005b. A novel subgroup of rhadinoviruses in ruminants. *Journal of General Virology* 86, 3021-3026.
- Li, H., Keller, J., Knowles, D.P., Crawford, T.B., 2001a. Recognition of another member of the malignant catarrhal fever virus group: an endemic gammaherpesvirus in domestic goats. *Journal of General Virology* 82, 227-232.
- Li, H., McGuire, T.C., Muller-Doblies, U.U., Crawford, T.B., 2001b. A simpler, more sensitive competitive inhibition enzyme-linked immunosorbent assay for detection of antibody to malignant catarrhal fever viruses. *Journal of Veterinary Diagnostic Investigation* 13, 361-364.
- Li, H., O'Toole, D., Kim, O., Oaks, J.L., Crawford, T.B., 2005a. Malignant catarrhal fever-like disease in sheep after intranasal inoculation with ovine herpesvirus-2. *Journal of Veterinary Diagnostic Investigation* 17, 171-175.
- Li, H., Shen, D.T., Davis, W.C., Knowles, D.P., Gorham, J.R., Crawford, T.B. 1995b. Identification and characterization of the major proteins of malignant catarrhal fever virus. *Journal of General Virology* 76, 123-129.
- Li, H., Shen, D.T., Jessup, D.A., Knowles, D.P., Gorham, J.R., Thorne, T., O'Toole, D., Crawford, T.B., 1996. Prevalence of antibody to malignant catarrhal fever virus in wild and domestic ruminants by competitive-inhibition ELISA. *Journal of Wildlife Diseases* 32, 437-443.
- Li, H., Shen D.T., Knowles D.P., Gorham J.R., Crawford T.B., 1994. Competitive-inhibition enzyme-linked-immunosorbent-assay for antibody in sheep and other ruminants to a conserved epitope of malignant catarrhal fever virus. *Journal of Clinical Microbiology* 32, 1674-1679.
- Li, H., Shen, D.T., O'Toole, D., Knowles, D.P., Gorham, J.R., Crawford, T.B., 1995a. Investigation of sheep-associated malignant catarrhal fever virus-infection in ruminants by PCR and competitive-inhibition enzyme-linked-immunosorbent-assay. *Journal of Clinical Microbiology* 33, 2048-2053.
- Li, H., Snowden, G., O'Toole, D., Crawford T.B., 1998. Transmission of ovine herpesvirus 2 in lambs. *Journal of Clinical Microbiology* 36, 223-226.
- Li, H., Taus, N.S., Lewis, G.S., Kim, O.J., Traul, D.L., 2004. Shedding of ovine herpesvirus 2 in sheep nasal secretions: the predominant mode for transmission. *Journal of Clinical Microbiology* 42, 5558-5564.

- Loken, T., Aleksandersen, M., Reid, H., Pow, I., 1998. Malignant catarrhal fever caused by ovine herpesvirus-2 in pigs in Norway. *Veterinary Record* 143, 464-467.
- Martucciello, A., Marianelli, C., Capuano, M., Astarita, S., Alfano, D., Galiero, G., 2006. An outbreak of malignant catarrhal fever in Mediterranean water buffalo (*Bubalus bubalis*). *Large Animal Review* 12, 21-24.
- McGeoch, D.J., Gatherer, D., Dolan, A., 2005. On phylogenetic relationships among major lineages of the Gammaherpesvirinae. *Journal of General Virology* 86, 307-316.
- McGeoch, D.J., Rixon, F.J., Davison, A.J., 2006. Topics in herpesvirus genomics and evolution. *Virus Research* 117, 90-104.
- Meteyer, C.U., Gonzales, B.J., Heuschele, W.P., Howard, E.B., 1989. Epidemiologic and pathologic aspects of an epizootic of malignant catarrhal fever in exotic hoofstock. *Journal of Wildlife Diseases* 25, 280-286.
- Mills, R., Rozanov, M., Lomsadze A., Tatusova, T. Borodovsky, M., 2003. Improving gene annotation of complete viral genomes. *Nucleic Acids Research* 31, 7041-7055.
- Milne, E.M., Reid, H.W., 1990. Recovery of a cow from malignant catarrhal fever. *Veterinary Record* 126, 640-641.
- Muller-Doblies, U.U., Li, H., Hauser, B., Adler, H., Ackermann, M., 1998. Field validation of laboratory tests for clinical diagnosis of sheep-associated malignant catarrhal fever. *Journal of Clinical Microbiology* 36, 2970-2972.
- Mushi, E.Z., Rurangirwa, F.R., Karstad, L., 1981. Shedding of malignant catarrhal fever virus by wildebeest calves. *Veterinary Microbiology* 6, 281-286.
- OIE, (2004) Malignant catarrhal fever. In: OIE Manual of Diagnostic Tests and Vaccines for Terrestrial Animal, fifth edition, France, pp. 570-579.
- O'Toole, D., Li H., Miller D., Williams W.R., Crawford T.B., 1997. Chronic and recovered cases of sheep-associated malignant catarrhal fever in cattle. *Veterinary Record* 140, 519-524.
- O'Toole, D., Li H., Sourk, C., Montgomery, D.L., Crawford T.B., 2002. Malignant catarrhal fever in a bison (*Bison bison*) feedlot, 1993–2000. *Journal of Veterinary Diagnostic Investigation* 14, 183–193.
- Patel, J.R., Edington, N., 1981. The detection and behaviour of the herpesvirus of malignant catarrhal fever in bovine lymphocytes. *Archives of Virology* 68, 321-326.
- Penny, C., 1998. Recovery of cattle from malignant catarrhal fever. *Veterinary Record* 142, 227.
- Piercy, S.E., 1954. Studies in bovine malignant catarrh. IV. Immunity and Vaccination. *British Veterinary Journal* 110, 87-96.
- Plowright, W., Ferris, R.D., Scott, G.R., 1960. Blue wildebeest and the aetiological agent of bovine malignant catarrhal fever. *Nature* 188, 1167-1169.
- Plowright, W., 1964. Studies on malignant catarrhal fever of cattle. PhD thesis, University of Pretoria, South Africa.
- Plowright, W., 1965. Malignant catarrhal fever in East Africa I. Behaviour of the virus in free-living populations of blue wildebeest. *Research in Veterinary Science* 6, 56-68.
- Plowright, W., 1967. Malignant catarrhal fever in East Africa III. Neutralizing antibody in free-living wildebeest. *Research in Veterinary Science*. 8, 129-136.
- Plowright, W., 1968. Malignant Catarrhal Fever. *Journal of the American Veterinary Medical Association*. 152, 795-804.
- Plowright, W., Herniman, K.A.J., Jesset, D.M., Kalunda, M., Rampton, C.S., 1975. Immunisation of cattle against the herpesvirus of malignant catarrhal fever: failure of inactivated culture vaccines with adjuvant. *Research in Veterinary Science* 19, 159-166.
- Powers, J.G., VanMetre, D.C., Collins, J.K., Dinsmore, R.P., Carman, J., Patterson, G., Brahmabhatt, D., Callan, R.J., 2005. Evaluation of ovine herpesvirus type 2 infections, as detected by competitive inhibition ELISA and polymerase reaction assay in dairy cattle without clinical signs of malignant catarrhal fever. *Journal of the American Veterinary Medical Association* 227, 606-611.
- Rech, R.R., Schild A.L., Driemeier D., Garmatz S.L., Oliveira F.N., Riet-Correa F., Barros C.S.L., 2005. Malignant catarrhal fever in cattle in Rio Grande do Sul, Brazil: Epidemiology, clinical signs and pathology. *Pesquisa Veterinaria Brasileira* 25, 97-105.
- Reid, H.W., Bridgen, A., 1991. Recovery of a herpesvirus from a roan antelope (*Hippotragus equinus*). *Veterinary Microbiology* 28, 269-278.
- Reid, H.W., Buxton D., 1984a. Malignant catarrhal fever of deer. *Proceedings of the Royal Society of Edinburgh B, Biological Sciences* 82, 261-273.
- Reid, H.W., Buxton D., Berrie E., Pow I., Finlayson J., 1984b. Malignant catarrhal fever. *Veterinary Record* 114, 581-583.
- Reid, H.W., Buxton D., Pow, I., Finlayson J., 1986. Malignant catarrhal fever - experimental transmission of the sheep-associated form of the disease from cattle and deer to cattle, deer, rabbits and hamsters. *Research in Veterinary Science* 41, 76-81.
- Reid, H.W., Buxton, D., Pow, I., Finlayson, J. 1989b. Isolation and characterization of lymphoblastoid-cells from cattle and deer affected with sheep-associated malignant catarrhal fever. *Research in Veterinary Science* 47, 90-96.
- Reid, H.W., Buxton, D., Pow, I., Finlayson, J., Berrie E.L. 1983. A cyto-toxic lymphocyte-T line propagated from a rabbit infected with sheep associated malignant catarrhal fever. *Research in Veterinary Science* 34, 109-113.
- Reid, H.W., Buxton D., McKelvey W.A.C., Milne J.A., Appleyard W.T., 1987. Malignant catarrhal fever in Pere-Davids deer. *Veterinary Record* 121, 276-277.

- Reid, H.W., Pow, I., Buxton D., 1989a. Antibody to alcelaphine herpesvirus-1 (AHV-1) in hamsters experimentally infected with AHV -1 and the sheep-associated agent of malignant catarrhal fever. *Research in Veterinary Science* 47, 383-386.
- Reid, S.W. Robinson, B.N., 1987. Malignant catarrhal fever in a 5-month-old calf. *Canadian Veterinary Journal* 28, 489.
- Rosbottom, J., Dalziel, R.G., Reid, H.W., Stewart, J.P., 2002. Ovine herpesvirus 2 lytic cycle replication and capsid production. *Journal of General Virology* 83, 2999-3002.
- Rossiter, P.B., 1981. Antibodies to malignant catarrhal fever virus in sheep sera. *Journal of Comparative Pathology* 91, 303-311.
- Rossiter, P.B., 1983. Antibodies to malignant catarrhal fever virus in cattle with non-wildebeest-associated malignant catarrhal fever. *Journal of Comparative Pathology* 93, 93-97.
- Schock, A., Collins, R.A., Reid, H.W., 1998. Phenotype, growth regulation and cytokine transcription in Ovine Herpesvirus-2 (OHV-2)-infected bovine T-cell lines. *Veterinary Immunology and Immunopathology* 66, 67-81.
- Schock, A., Reid, H.W., 1996. Characterisation of the lymphoproliferation in rabbits experimentally affected with malignant catarrhal fever. *Veterinary Microbiology* 53, 111-119.
- Schultheiss, P.C., Collins, J.K., Spraker, T.R., DeMartini, J.C., 2000. Epizootic malignant catarrhal fever in three bison herds: differences from cattle and association with ovine herpesvirus- 2. *Journal of Veterinary Diagnostic Investigation* 12, 497-502.
- Simon, S., Li, H., O'Toole, D., Crawford, T.B., Oaks, J.L., 2003. The vascular lesions of a cow and bison with sheep-associated malignant catarrhal fever contain ovine herpesvirus 2-infected CD8<sup>+</sup> T lymphocytes. *Journal of General Virology* 84, 2009-2013.
- Swa, S., Wright, H., Thomson, J., Reid, H., Haig, D., 2001. Constitutive activation of Lck and Fyn tyrosine kinases in large granular lymphocytes infected with the gamma-herpesvirus agents of malignant catarrhal fever. *Immunology* 102, 44-52.
- Syrjälä, P., Saarinen, H., Laine, T., Kokkonen, T., Veijalainen, P., 2006. Malignant catarrhal fever in pigs and a genetic comparison of porcine and ruminant virus isolates in Finland. *Veterinary Record*. 159, 406-409.
- Taus, N.S., Herndon, D.R., Traul, D.L., Stewart, J.P., Ackermann, M., Li, H., Knowles, D.P., Lewis, G.S., Brayton, K.A., 2007. Comparison of ovine herpesvirus 2 genomes isolated from sheep (*Ovis aries*) and a clinically affected cow (*Bos bovis*). *Journal of General Virology* 88, 40-45.
- Taus, N.S., Oaks, J.L., Gailbreath, K., Traul, D.L., O'Toole, D., Li, H., 2006. Experimental aerosol infection of cattle (*Bos taurus*) with ovine herpesvirus 2 using nasal secretions from infected sheep. *Veterinary Microbiology* 116, 29-36.
- Taus, N.S., Traul, D.L., Oaks, J.L., Crawford, T.B., Lewis, G.S., Li H., 2005. Experimental infection of sheep with ovine herpesvirus 2 via aerosolization of nasal secretions. *Journal of General Virology* 86:575-579.
- Thonur, L., Russell, G.C., Stewart, J.P., Haig, D.M., 2006. Differential transcription of ovine herpesvirus 2 genes in lymphocytes from reservoir and susceptible species. *Virus Genes* 32, 27-35.
- Traul, D.L., Elias, S., Taus, N.S., Herrmann, L.M., Oaks, J.L., Li, H., 2005. A real-time PCR assay for measuring alcelaphine herpesvirus-1 DNA. *Journal of Virological Methods* 129, 186-190.
- Vikoren, T., Li, H., Lillehaug, A., Jonassen, C.M., Bockerman, I., Handeland, K., 2006. Malignant catarrhal fever in free-ranging cervids associated with OvHV-2 and CpHV-2 DNA. *Journal of Wildlife Diseases* 42, 797-807.
- Whitaker, K.A., Wessels, M.E., Campbell, I., Russell, G.C., 2007. An outbreak of wildebeest-associated malignant catarrhal fever in Ankole cattle. *Veterinary Record* 161, 692-695.
- Wilkinson, J.M., Galea-Lauri, J., Reid, H.W., 1992. A cytotoxic rabbit T-cell line infected with a  $\gamma$ -herpes virus which expresses CD8 and class II antigens. *Immunology* 77, 106-108.
- Wilson, P.R., 2002. Advances in health and welfare of farmed deer in New Zealand. *New Zealand Veterinary Journal* 50, 105-109.
- Wiyono, A., Baxter S.I.F., Saepulloh M., Damayanti R., Daniels P., Reid H.W., 1994. PCR detection of ovine herpesvirus-2 DNA in Indonesian ruminants - normal sheep and clinical cases of malignant catarrhal fever. *Veterinary Microbiology* 42, 45-52.
- Wright, H., Stewart, J.P., Ireri, R.G., Campell, I., Pow, I., Reid, H.W., Haig, D.M., 2003. Genome re-arrangements associated with loss of pathogenicity of the  $\gamma$ -herpesvirus alcelaphine herpesvirus-1. *Research in Veterinary Science* 75, 163-168.
- Yus, E., Guitian, J., Diaz, A., Sanjuan, M.L., 1999. Outbreak of malignant catarrhal fever in cattle in Spain. *Veterinary Record* 145, 466-467.
- Zarnke, R.L., Li, H., Crawford, T.B., 2002. Serum antibody prevalence of malignant catarrhal fever viruses in seven wildlife species from Alaska. *Journal of Wildlife Diseases* 38, 500-504.